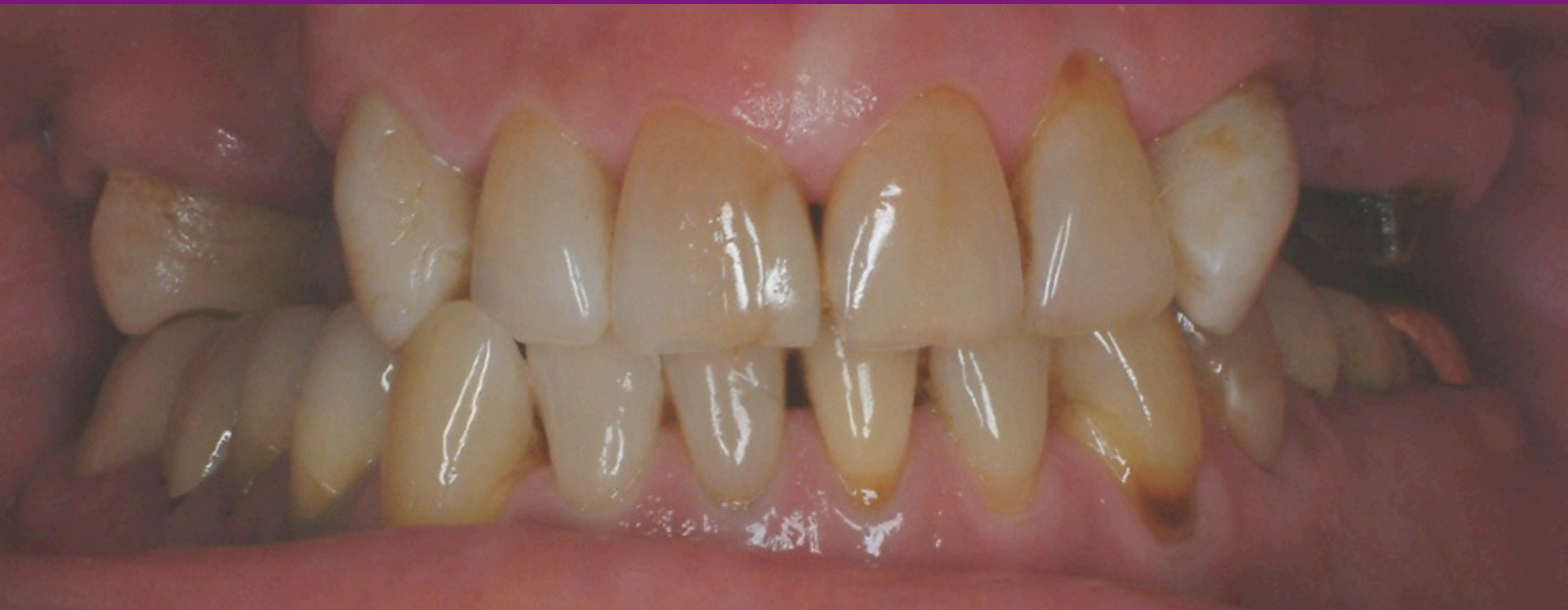
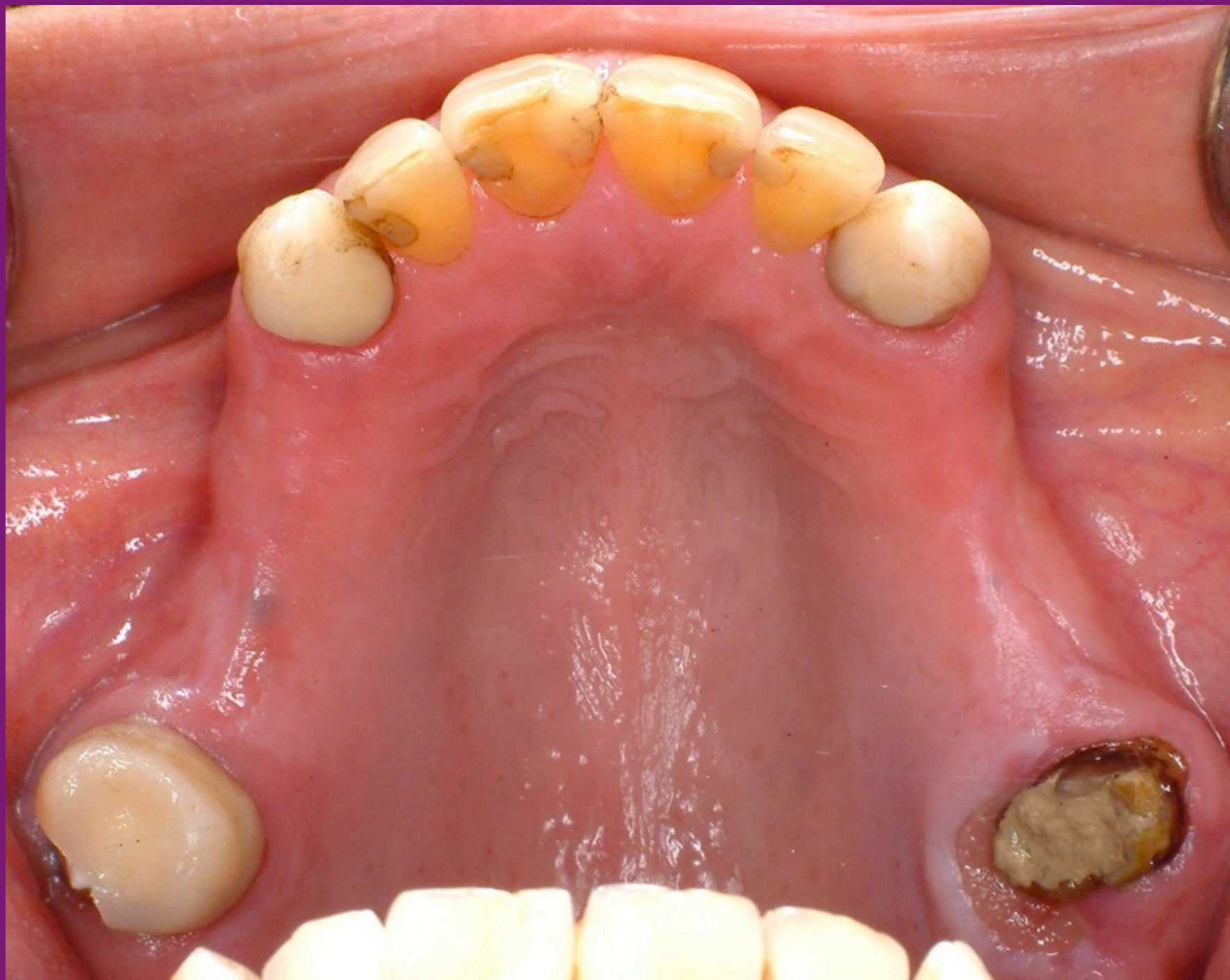


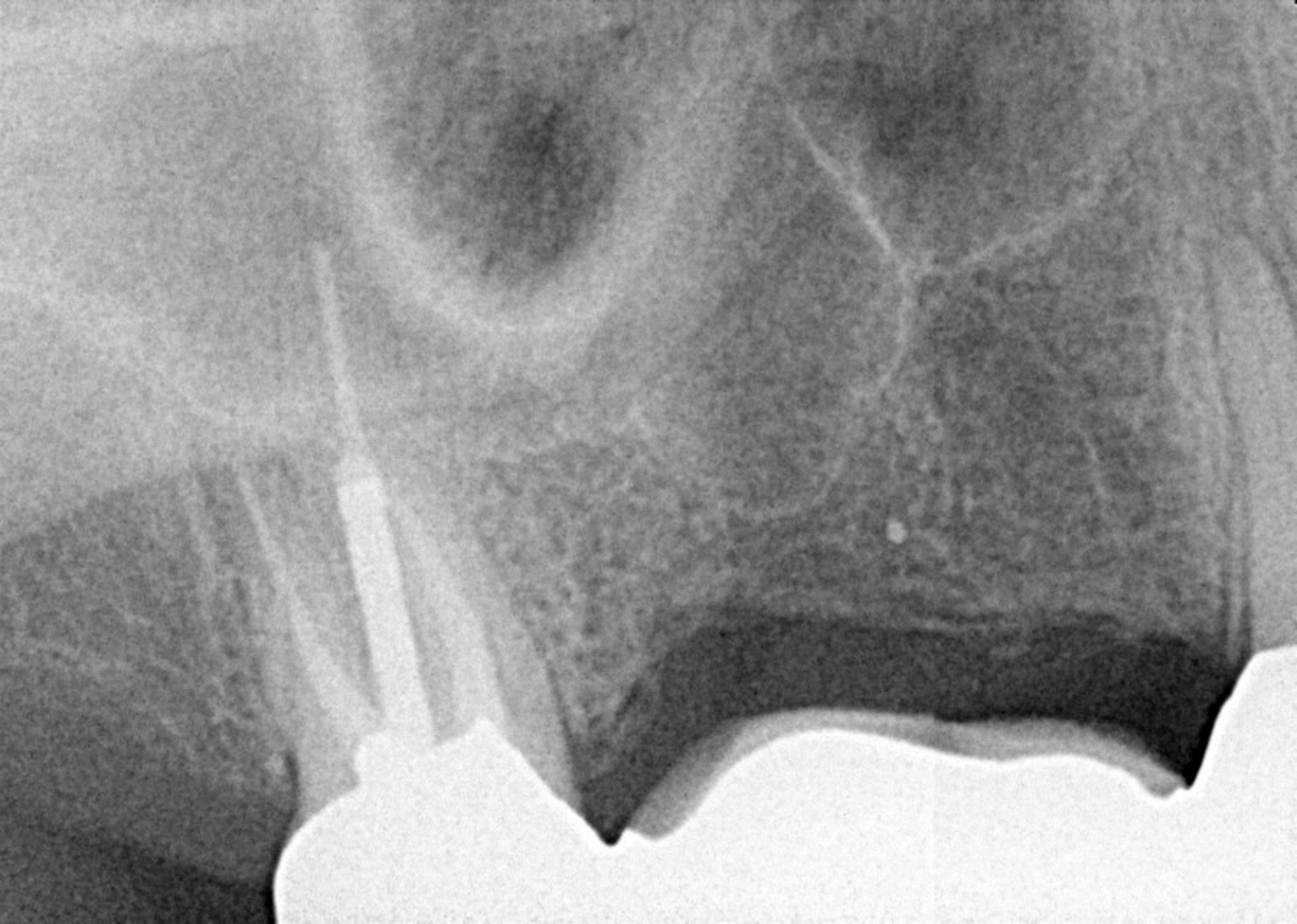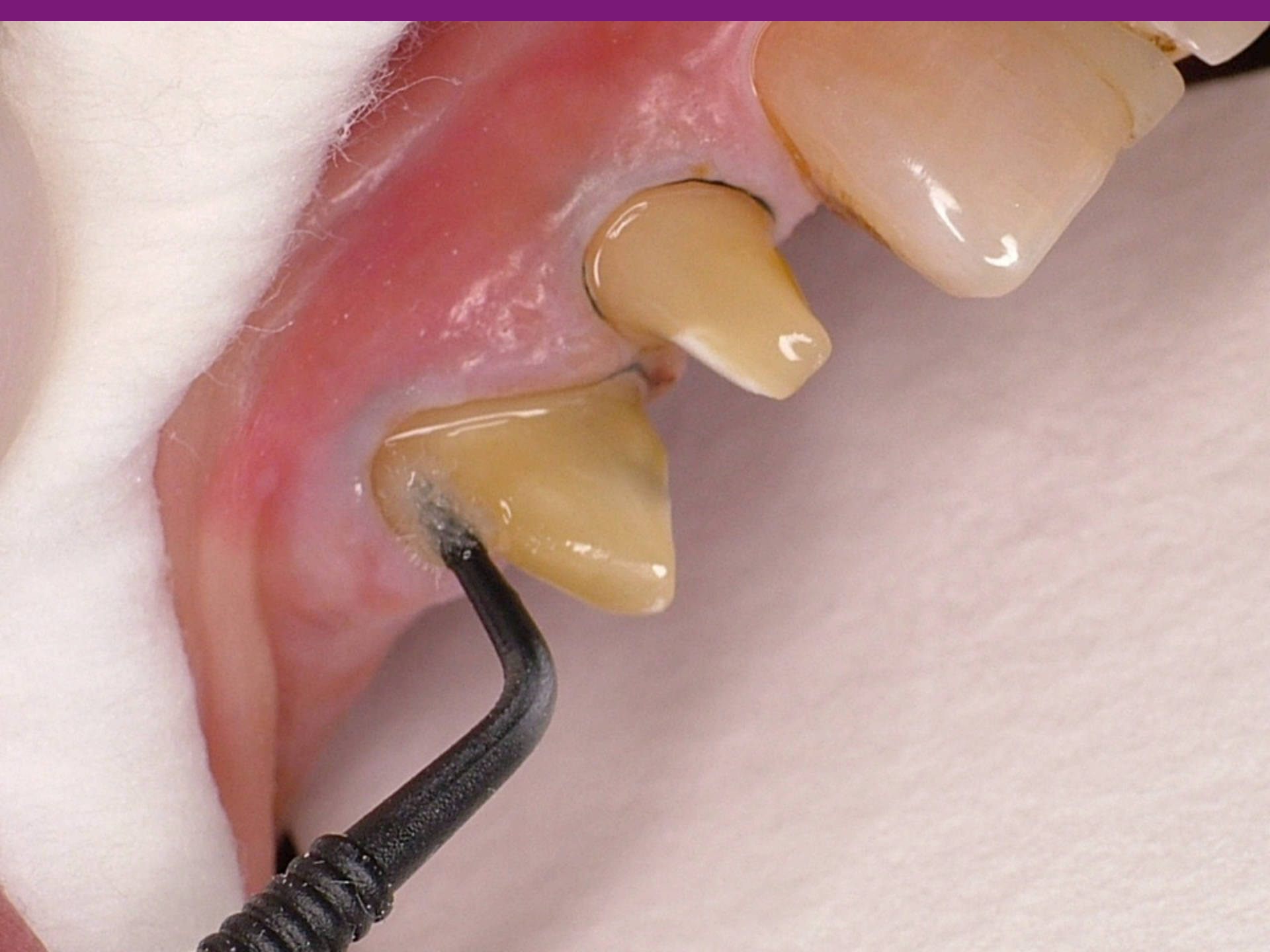
Lori – upper jaw teeth broken down – implants refused.



8 remaining teeth

- Missing two premolars and one molar each side
- Next image is a root canal filling and post in upper right molar.

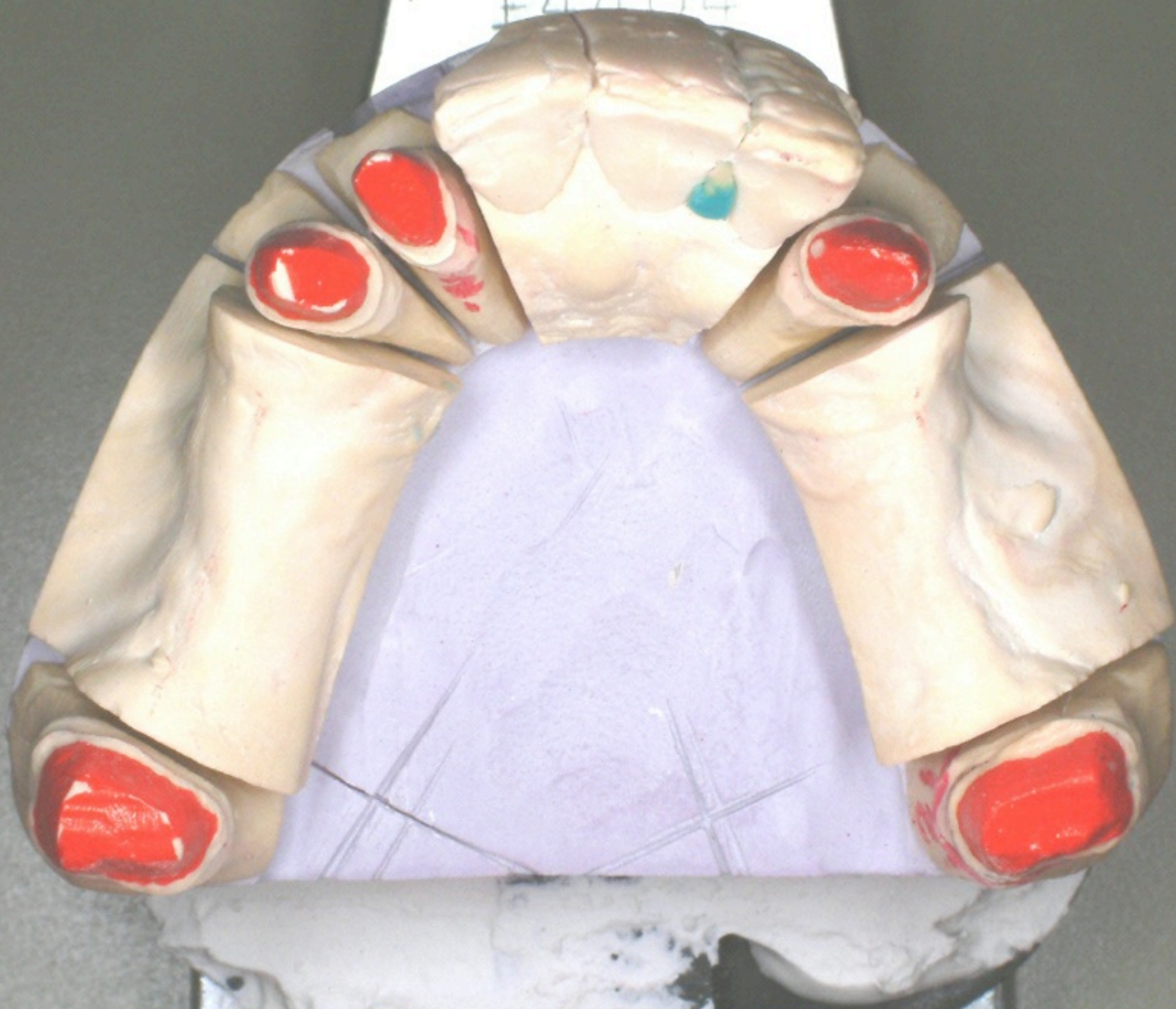


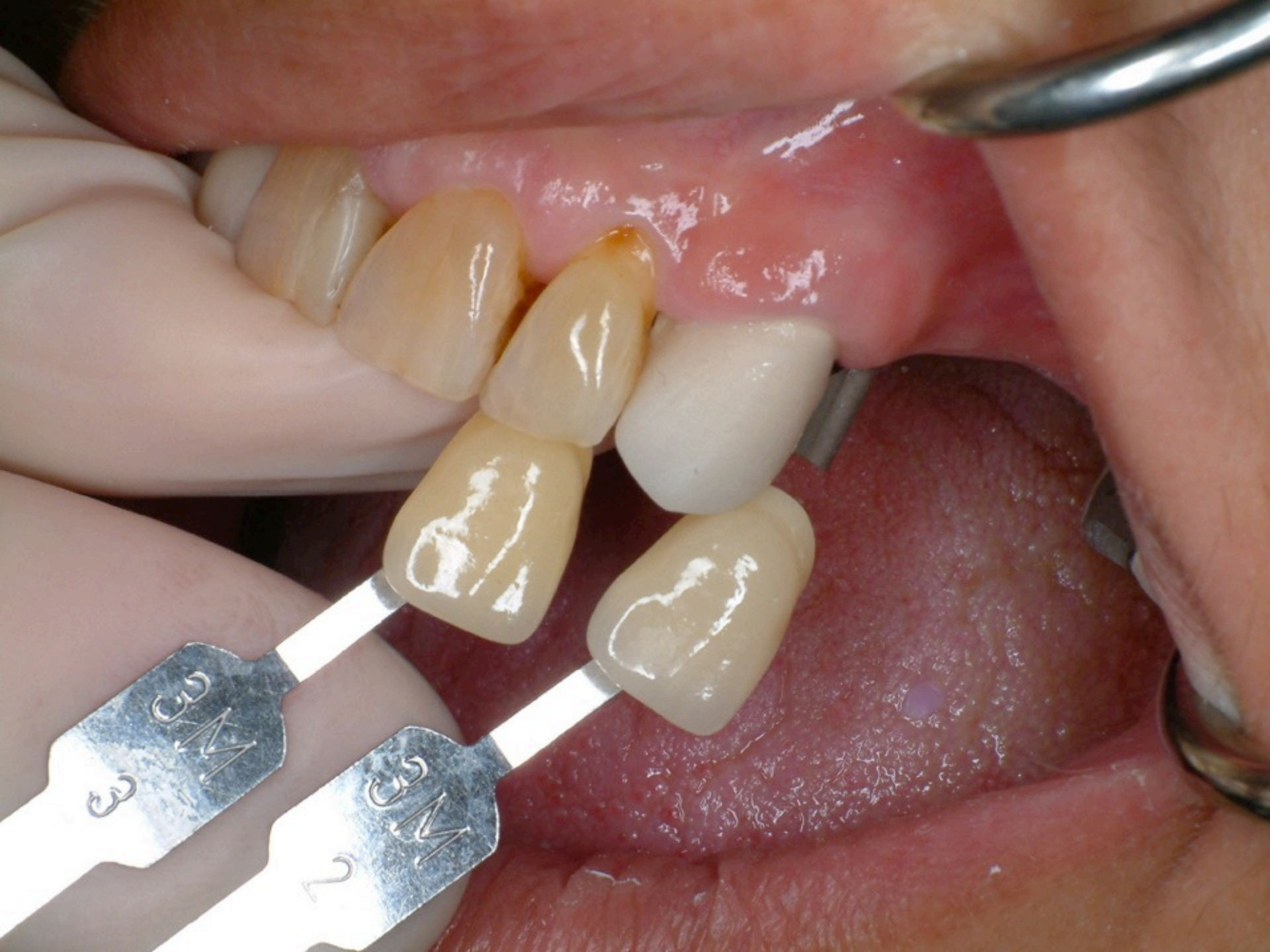

Teeth are prepared on each side of spaces.

- Red images are tooth preparations on master cast.
- Coating of the teeth with a protective coating to reduce sensitivity.

14404





Shade selection – then

- This is a precision attachment retained removable upper partial denture.
- Retentive elements are included on the crowns and inside the partial so that there is no clasps to be seen.
- An extremely stable combination .





